

# Effect of umbilical cord-derived mesenchymal stem cell secretome on intima-media thickness (IMT) in severe erectile dysfunction non-response to sildenafil

Nugroho M,I<sup>a</sup> Atmadja. H,S<sup>b</sup>, Rahardjo, P<sup>b</sup>, Supardi<sup>c</sup>

<sup>a</sup> *m.ikhsan.nugroho-2020@fk.unair.ac.id*

*a Resident of Study Program of Radiology, Faculty of Medicine, Airlangga University*

*b Staff of Department of Radiology, Faculty of Medicine, Airlangga University*

*c Staff of Department of Andrology, Faculty of Medicine, Airlangga University*

## Abstract

**Background:** Erectile dysfunction (ED) is defined as the inability to obtain and maintain a penile erection adequately for sexual intercourse consistently for a period of 3 months. Current treatments for erectile dysfunction were aimed on a temporary basis and do not have a permanent effect on disruption of the endothelium or homeostasis of the penile tissue. The stem cell secretome is a bioactive substance that has active components, namely VEGF and NGF, which are known to prevent ED through their pro-angiogenic and neuro-regenerative/neurotrophic properties. **Objective:** The objective of this study was to analyze the effect of secretome of umbilical cord mesenchymal stem cell (UC-MSCs) on intima-media thickness (IMT) of the cavernous arteries in patients with severe erectile dysfunction non-respond to sildenafil. **Method:** The research used a pre-post-test design which was carried out from April to May 2024. Evaluation of the IMT using ultrasound on the flaccid state, without injection of erectile agent, examined before and one month after intracavernous injection the secretome of UC-MSc. **Results:** Seven patients aged 54-65 years were obtained who met the inclusion and exclusion criteria. There are statistically significant changes of IMT on the proximal and mid part of the right side of corpus cavernosum following the intervention, but there are not statistically significant changes on the other part of the corpus cavernosum. **Conclusion :** the dominant IMT changes were not statistically significant, namely on the right distal side and left proximal-mid-distal, but they were statistically significant on the right proximal-mid side.

Keywords: Erectile dysfunction; secretome; intima-media thickness

## 1. Background

Erectile dysfunction (ED) is defined as the inability to achieve and maintain a penile erection adequate for sexual intercourse consistently for a period of 3 months.(Miller, 2000) ED can have a profound impact, in the form of stress and anxiety about sex, low self-esteem, fertility-related problems, relationship problems with partners, and depression. The prevalence of ED in the Indonesian population ranges from 6.5% in the 20-29 age group to 88.0% in respondents aged 60 years and over (Birowo et al., 2019). The most common causes of ED are neurogenic and vasculogenic.

Ultrasound is a non-invasive and radiation-free diagnostic method, which reliable for assessing penile hemodynamics.(Lue, 2000) Ultrasound can assess the diameter of the cavernosum artery, intima-media thickness (IMT), Peak Systolic Velocity (PSV), End Diastolic Velocity (EDV) and Resistive Index (RI)

(Gatkin and Sopotov, 2018; Sen et al., 2007). But this article will be focused in IMT. Shabsigh, stated that an increase in carotid IMT with ultrasound examination showed the earliest systemic morphological changes in the arterial wall (Shabsigh et al., 2008). Increased IMT is a morphological and structural change in the blood vessel wall due to atherosclerotic formation. Penile ultrasound examination in flaccid state could also describe the penis condition as in erect state (Gatkin and Sopotov, 2018; Sen et al., 2007).

Nowadays, the available erectile dysfunction treatments aim to increase the ability of the penis to have a temporary erection and do not have a permanent effect on endothelial disorders or penile tissue homeostasis. Commonly used drug classes are phosphodiesterase-5 inhibitors (PDE5i), intra-corporal injection, vacuum devices, and prosthesis implantation. PDE5i consisting of sildenafil, vardenafil, tadalafil, and avanafil are the first-line treatments for erectile dysfunction (Wang et al., 2023). However, the increasing number of patients who do not respond to PDE5i. Intra-corporal injection (ICI) such as papaverine and prostaglandin E1 to induce penile erection is a breakthrough in the treatment of ED. However, the clinical application of ICI has gradually declined, because it is associated with priapism, ecchymosis, hematoma, and penile fibrosis (Belew et al., 2015). Vacuum erection device (VED) is a mechanical device that can increase blood flow to the corpus cavernosum by creating a vacuum environment and has a retaining ring at the root of the penis to improve erection, but nearly 28.6% of patients reported physical discomfort when using VED, usually due to pain caused by the retaining ring. Penile prosthesis implantation (PPI) is currently the third-line treatment for ED. It is usually considered when oral PDE5i drugs, intracavernous injections, and VED therapy are ineffective. However, PPI is expensive, traumatic, and prone to complications, such as prosthetic infection, pump migration, and others (Wang et al., 2023).

Curative therapy that is currently being developed can also be an option, namely stem cell-based therapy. Stem cell secretome is a bioactive substance that has active components, namely VEGF and NGF, which are known to prevent ED through their pro-angiogenic and neuro-regenerative properties (Sun et al., 2019). In a literature review study, it was stated that local injection (mesenchymal stem cells) MSC intravenously into injured blood vessels in experimental animal models produced the desired effect of reducing the thickness of the intima-media tunica (Zhu et al., 2010).

## 2. Method

This study was conducted at the Radiology Department of Dr. Soetomo Hospital from April to May 2024. This is experimental research with pre-post-test design. Researchers conduct sample selection, parameter measurements before the intervention called the pre-test, then intervention is carried out, and finally an examination is carried out after the intervention called the post-test. The difference between the observation results before and after the intervention is considered the effect of the intervention given (Effendi, 2013).

With inclusion criteria, patients aged 40-65 years that has severe ED with organic factors for at least 6 months with an IIEF-5 score between 5-7. Has received sildenafil 100 mg 4 times. Type II Diabetes Mellitus with HbA1c examination results <7%. Laboratory results of liver and kidney function tests are within normal limits. Married and still living with his wife. Willing and signing informed consent.

With Exclusion Criteria, clinically visible anatomical abnormalities of the penis. Active and significant systemic or local infection. History of therapy for bleeding or blood clotting disorders. History of systemic autoimmune disorders or immunosuppressive treatment. History of prostate surgery, history of malignancy or PSA values > 4 ng / mL. Untreated hypogonadism or low total serum testosterone (<200 µg / dL).

The ultrasound evaluation carried out in the flaccid phase, according to the results of several studies which stated that evaluation of the flaccid vase alone was able to describe the condition of the penis just like when it is in an erect condition. The results of the ultrasound examination will obtain several parameter results, but in this article will focus only on IMT. The data obtained will be inputted and processed with the SPSS 27.0 for

Macintosh TM program. Descriptive data presentation is carried out to determine the characteristics of all data held to determine the mean and standard deviation. A statistically significant test result ( $P \leq 0.05$ ) means that the test hypothesis is false or should be rejected. P value greater than 0.05 means that no effect was observed (Grabowski, 2016).

### 3. Result

This study used a sample of 7 patients with severe ED non-response to sildenafil who met the inclusion and exclusion criteria, in the age range of 40-65 years with the youngest patient being 54 years old and the eldest being 65 years old with an average 61 years. Ultrasound examination was performed at the Radiology Installation of RSUD dr. Soetomo Surabaya using a General Electric Type Logic P8. The results of liver and kidney function examinations were within normal limits with an average SGOT of 21.57 U/L and a median SGPT value of 16 U/L. The average urea was 15.50 mg/dL and creatinine were 1.07 mg/dL. The study subjects had a history of controlled type 2 diabetes mellitus with an average HbA1c of 6.02%. The median PSA value was 1.40 ng/mL, and the average testosterone was 675.6 ng/dL. With these characteristic data, it is expected that patients are in almost the same physiological condition.

Table 1. Characteristics of research subjects. Numerical data are presented as mean  $\pm$  SD for normal distribution, and median (min-max) for non-normal distribution.

Characteristics		N=7
<b>Age</b>	mean $\pm$ SD	61.14 $\pm$ 3.89
IIEF-5	median (min-max)	5 (5 – 7)
SGOT	mean $\pm$ SD	21.57 $\pm$ 6.70
SGPT	median (min-max)	16 (9 – 49)
Ureum	mean $\pm$ SD	15.50 $\pm$ 4.72
Creatinine	mean $\pm$ SD	1.07 $\pm$ 0.01
HbA1c	mean $\pm$ SD	6.02 $\pm$ 0.73
PSA	median (min-max)	1.40 (0.90 – 4)
<b>Testosterone</b>	mean $\pm$ SD	675,6 $\pm$ 302,27

Ultrasound examination in greyscale mode, varying IMT on the proximal, mid, and distal sides, with the lowest IMT is 0.02 cm, the highest is 0.09 cm, with average is 0.039. Evaluation one month after administration of secretome, varying changes in IMT were found, with the lowest value of 0.02 cm and the highest of 0.05 cm, with an average of 0.031. Using the Wilcoxon test and paired T test to analyze the differences in IMT before and after administration of secretome. Significant results were obtained ( $p < 0.05$ ) in the right proximal-mid IMT, and not significant ( $p > 0.05$ ) in the right distal, left proximal-mid-distal IMT.

Table 2 Cavernous artery IMT pre and post injection

Cavernous artery IMT		Mean	SD	Difference	p
Right	<i>Proximal pre</i>	0,04	0,01	0,01	0,001 <sup>a</sup>
	<i>Proximal post</i>	0,03	0,01		
	<i>Mid pre</i>	0,04	0,01		
	<i>Mid post</i>	0,03	0,01	0,008 <sup>a</sup>	
	<i>Distal pre</i>	0,04	0,01		
	<i>Distal post</i>	0,03	0,01		
Left	<i>Proximal pre</i>	0,04	0,01	0,01	0,157 <sup>b</sup>
	<i>Proximal post</i>	0,03	0,01		
	<i>Mid pre</i>	0,04	0,01		
	<i>Mid post</i>	0,03	0,00	0,059 <sup>b</sup>	
	<i>Distal pre</i>	0,04	0,01		
	<i>Distal post</i>	0,03	0,01		

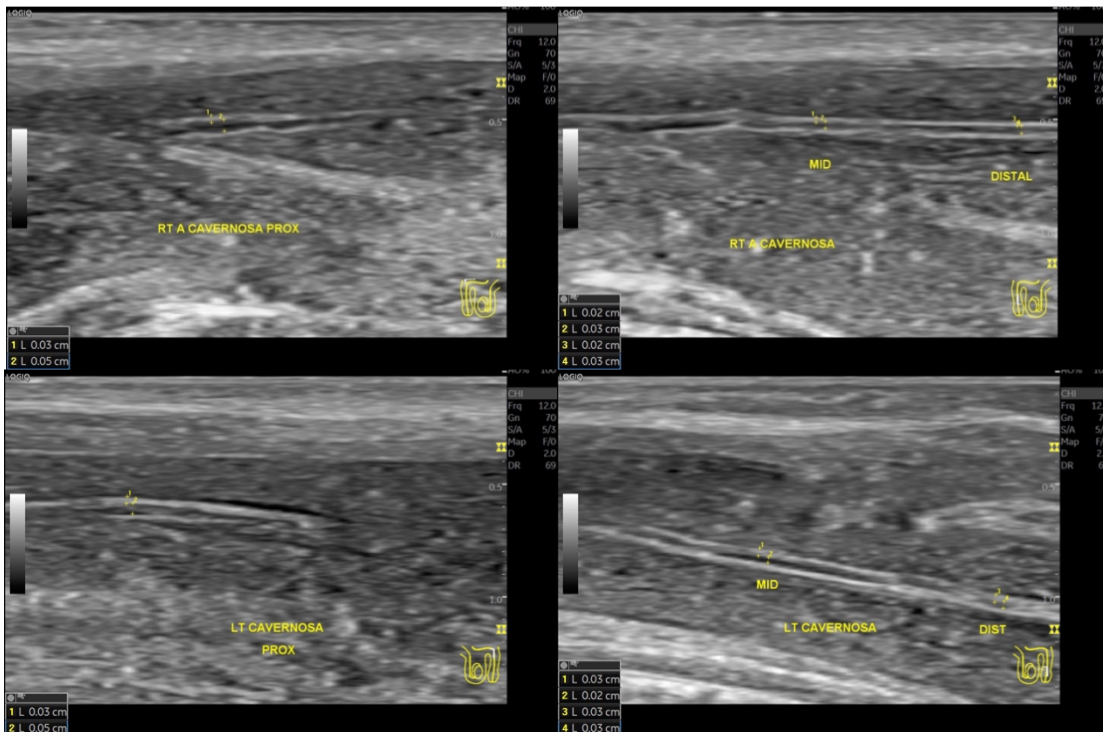


Figure 2. Evaluation of IMT using longitudinal greyscale ultrasound.

#### 4. Discussion

The earliest detectable change in vascular disease in ED patients is an abnormality in the endothelium, which causes the loss of normal homeostatic mechanisms. The normal penile erection process requires vasodilation that depends on relaxation of arterial endothelial and sinusoidal endothelial smooth (Bivalacqua et al., 2003). The secretome regeneration effect will trigger endothelial cell differentiation, which will increase the function of the cavernous arterial endothelium and increase relaxation of the corpus cavernosum smooth muscle (Bivalacqua et al., 2003). From the results of this study, the IMT values were obtained which varied before and after 1 month of secretome injection. The average difference in IMT between before and after secretome administration was 0.01 cm with an average thickness before of 0.04 cm and an average after of 0.03 cm. In statistical analysis, although the changes were predominantly not statistically significant, namely on the right distal side and left proximal-mid-distal, but statistically significant on the right proximal-mid side. This shows that the regeneration effect of secretome is quite promising and need for further research.

## 5. Conclusion

The difference in mean IMT between before and after administration of umbilical cord mesenchymal stem cell secretome was 0.01 cm with an average thickness before of 0.04 cm and an average after of 0.03 cm. In statistical analysis, although the dominant IMT changes were not statistically significant, namely on the right distal side and left proximal-mid-distal, but they were statistically significant on the right proximal-mid side.

## Acknowledgements

I would like to dedicate my gratitude to all the lecturers of Radiology, Faculty of Medicine Universitas Airlangga, my family, and my friends for their endless support.

## References

- Belew D, Klaassen Z and Lewis RW (2015) Intracavernosal Injection for the Diagnosis, Evaluation, and Treatment of Erectile Dysfunction: A Review. *Sexual Medicine Reviews*. Blackwell Publishing Ltd.
- Birowo P, Deswanto IA and Rasyid N (2019) Epidemiology of erectile dysfunction: A cross-sectional web-based survey conducted in an Indonesian national referral hospital. *F1000Research* 8: 817.
- Bivalacqua TJ, Usta MF, Champion HC, et al. (2003) Endothelial Dysfunction in Erectile Dysfunction: Role of the Endothelium in Erectile Physiology and Disease. *Journal of Andrology* 24(S6).
- Effendi MS (2013) Desain eksperimental dalam penelitian pendidikan. *Jurnal Perspektif Pendidikan* 6(1).
- Gatkin M and Sopotov A (2018) 557 Doppler Test in Penis Flaccid State to Assess Erectile Dysfunction Severity and Shockwave Treatment Outcomes. *The Journal of Sexual Medicine* 15(Supplement\_3): S331–S332.
- Grabowski B (2016) ‘P < 0.05’ Might Not Mean What You Think: American Statistical Association Clarifies P Values. *Journal of the National Cancer Institute* 108(8).
- Lue TF (2000) Erectile Dysfunction. *New England Journal of Medicine* 342(24): 1802–1813.
- Miller TA (2000) Diagnostic Evaluation of Erectile Dysfunction ". *Am Fam Physician*. Available at: <https://www.aafp.org/afp/2016/1115/p820.html>.
- Sen J, Godara R, Singh R, et al. (2007) Colour Doppler sonography of flaccid penis in evaluation of erectile dysfunction. *Asian journal of surgery* 30(2): 122–5.
- Shabsigh R, Shah M and Sand M (2008) Erectile dysfunction and men’s health: developing a comorbidity risk calculator. *The journal of sexual medicine* 5(5): 1237–1243.
- Sun DZ, Abelson B, Babbar P, et al. (2019) Harnessing the mesenchymal stem cell secretome for regenerative urology. *Nature reviews. Urology* 16(6): 363–375.
- Wang CM, Wu BR, Xiang P, et al. (2023) Management of male erectile dysfunction: From the past to the future. *Frontiers in Endocrinology*. Frontiers Media S.A.
- Zhu S, Malhotra A, Zhang L, et al. (2010) Human umbilical cord blood endothelial progenitor cells decrease vein graft neointimal hyperplasia in SCID mice. *Atherosclerosis* 212(1): 63–9.