

The Effect of Topical Ambergris *Physeter Macrocephalus* on Epithelialization in Second Degree Burns in Rats

Dede Erdina Wirza^{a*}, Adi Muradi Muhar^b, Arya Tjipta Prananda^c, Putri Chairani Eyanoer^d, Iqbal Pahlevi Adeputra Nasution^e

^aDepartment of Surgery, Faculty of Medicine, University of North Sumatra

^bDivision of Digestive Surgery, Department of Surgery, Faculty of Medicine, University of North Sumatra

^cDivision of Plastic Surgery, Department of Surgery, Faculty of Medicine, University of North Sumatra

^dDepartment of Community Medicine, Faculty of Medicine, University of North Sumatra

^eDivision of Pediatric Surgery, Department of Surgery, Faculty of Medicine, University of North Sumatra

Abstract

Introduction: Burn injuries represent a significant global health concern, with high prevalence and mortality rates worldwide, including in Indonesia. Current treatment methods for burns face challenges such as antibiotic resistance and limited regenerative techniques, necessitating innovative solutions. *Physeter Macrocephalus* ambergris has emerged as a promising candidate due to its anti-inflammatory and antibacterial properties, potentially aiding in wound healing.

Methods: A true experimental design was employed to investigate the effect of topical application of *Physeter Macrocephalus* ambergris on second-degree burn wounds in a rat model. Four groups were studied over 21 days, with histological evaluations performed. Statistical analysis was conducted using univariate analysis and ANOVA/Kruskal-Wallis tests.

Results: *Physeter Macrocephalus* ambergris oil significantly promoted epithelialization compared to controls on both the 14th and 21st days. Neutrophil levels were significantly reduced in the ambergris-treated group compared to the negative control, indicating improved wound healing. However, no significant differences were observed between ambergris-treated groups and those treated with NaCl or vaseline.

Discussion: *Physeter Macrocephalus* ambergris oil demonstrated a notable effect on epithelialization and wound closure, potentially attributed to its bioactive compounds. Faster re-epithelialization was observed, suggesting accelerated wound healing. The study underscores the potential of ambergris oil as a novel modality for burn treatment

Keywords: Type your keywords here, separated by semicolons ;

1. Introduction

Burns, as a global health problem, poses major challenges in the medical and research fields. The epidemiology of burns shows a high prevalence throughout the world, including in Indonesia, where the incidence of burns is often associated with various daily activities and working conditions.¹ According to the latest data from the World Health Organization (WHO), burns cause more than 265,000 deaths every year

worldwide. In Indonesia, burns are a common cause of disability and death, especially among children and young adults, requiring special attention to prevention and treatment strategies.²

Second-degree burns in particular, result in damage not only to the epidermis but also penetrate into the dermis, triggering a complex inflammatory response and initiating the healing process. Epithelialization, a critical stage in wound healing, involves migration, proliferation, and differentiation of epithelial cells to form a new layer covering the wound. This process is essential for restoring skin integrity and function, but can be hampered by various factors, including microbial contamination and local wound conditions.³ Current treatment options for burns include a variety of methods, from conventional wound management such as wound cleaning and closure, to the use of topical agents to prevent infection, to regenerative techniques such as cell therapy. However, challenges such as antibiotic resistance and limitations of regenerative techniques drive the continuous search for innovative solutions.^{2,3}

In this context, *Physeter Macrocephalus ambergris* emerged as a promising candidate. *Physeter Macrocephalus ambergris*, found in the intestines of sperm whales, has been used since ancient times in a variety of applications, including as a component in perfumes and medicines. Its unique chemical composition, including compounds such as ambrein, has anti-inflammatory and antibacterial potential, which supports its application in wound healing.⁴ Recent research shows that topical application of *Physeter Macrocephalus ambergris* to burn wounds can facilitate the epithelialization process by reducing inflammation and accelerating structural recovery skins. This fact paves the way for the development of new therapies that are more effective in managing burn wounds, especially in accelerating healing and reducing the risk of post-injury complications.⁵

Therefore, this study was designed to systematically explore the effect of topical administration of *Physeter Macrocephalus ambergris* on the epithelialization of second-degree burn wounds in a rat animal model. Through an experimental approach, this research aims to provide scientific evidence that can support the use of *Physeter Macrocephalus ambergris* as an alternative treatment for burns, with the hope of improving clinical outcomes and quality of life for patients who experience burns. Thus, the results of this research are expected to make a significant contribution to medical literature and clinical practice, as well as offering new solutions in the treatment of burns that are safer and more effective.

2. Methods

The design of this research is a true experiment using laboratory animal experimental design (Laboratory Animal Experimental Design) to analyze the effect of topical administration of *Physeter macrocephalus ambergris* on experimental animal models of second-degree fire burns. The overall research (including processing of the main intervention, namely *Physeter macrocephalus ambergris*) was carried out at the Pharmacy Laboratory, Faculty of Pharmacy, University of North Sumatra, Medan, Indonesia. Histological examination was carried out at the Anatomical Pathology Laboratory, Prospecta, North Sumatra, Medan, Indonesia in January 2024 for 0 - 21 days. This research itself will apply 4 different groups to be evaluated for 21 days, namely:

1. Negative control group (group A): experimental animals that did not receive any treatment, which will be measured as a comparison.
2. Positive control group (group B); Experimental animals that received second degree fire burns were induced with moist gauze with 0.9% NaCl, the intention was to heal.
3. Control group (group C); experimental animals received second-degree fire burn induction and were given vaseline (according to the study by Vaghardoost et al.).

4. Experimental group (group D); experimental animals that received second degree burns and were given pure topical *Physeter macrocephalus ambergriis* oil (100%).

The inclusion criteria for this study were that Wistar albino rats of male sex and adult age were used to avoid hormonal influences as much as possible on the research results and the measured body mass of the rats before and after the acclimatization process was completed in the range of 150-200 grams. The exclusion criteria were albino Wistar rats that had been infected with pathogens that were feared to affect the final study outcomes. Drop Out criteria are Wistar albino mice that have been infected and died and the mice appear sick (inactive movements, not wanting to eat, dull or falling out hair).

The minimum number of samples required for each group is 7 mice, with the total number of mice required in this study for 4 groups being 28 male Wistar albino mice. Regarding anticipating the drop out rate, 20% was added to the calculation results in this study so that 8 individuals were needed from each group. In this study, subjects were added to 9 mice per group to reduce bias and increase the sharpness of the results. The total number of mice used in this study was 36 mice.

The risk of morbidity from sham surgery in this study was classified as minor (performed on non-active areas such as the trunk, and did not involve active areas such as the legs and joints). Regarding the treatment in administering ambegris, rats whose backs had been shaved with a 2x3 cm area were injured with a plate at 105 degrees for 15 seconds, then the ambergriis was taken into a cup, then heated until the ambegris became liquid and took the form of oil, then rubbed onto the burnt area. The next step is histological assessment. Skin samples that had burns were taken by excision or small incision on the 14th and 21st days from the number that had been dropped out. The skin sample will be fixed with formalin. Embed it using a paraffin block. Stain the tissue using eosin. Observe the histological findings under a microscope (using immersion oil) to obtain an accurate interpretation of anatomical pathology.

The main instruments that researchers use to collect variable data are physical examination, laboratory examination, and histological evaluation. Univariate analysis was carried out to obtain the distribution of sample characteristics. Data analysis will be carried out in categorical form, average (mean) \pm standard deviation (SD) if the data is normally distributed, and median (IQR, interquartile range) if the data is not normally distributed. Researchers will analyze data findings using the one-way ANOVA test for normal data and the Kruskal-Wallis test for data that is not normally distributed considering that the research independent variable has >2 treatments with the dependent variable in numerical data. Analysis will be carried out using statistical software.

3. Results

The research was carried out by observing the epithelialization of 2nd degree burn wound models on the 14th day and 21st day in four groups, presented in table 1. Based on the number of subjects the sample calculation for each group was 9 samples per group with a total of 36 samples, taking into account drop-outs, in the research observations the total sample was 34 samples consisting of 8 negative control samples, 9 samples given vaseline, 8 samples given normal saline (NaCl), and 9 samples given *Physeter macrocephalus ambergriis* oil. . The epithelialization preparations were observed under a microscope with a magnification of 400x, then interpretation of the epithelialization was carried out based on the histopathological scoring parameters as follows: score 0 if there is thickness of the wound edges, score 1 if there is cell movement (<50%), score 2 if there is cell movement (\geq 50%), score 3 if there is closure of the excision, and score 4 if there is keratinization.

Table 1.Differences in epithelialization processes between groups

| Days/ Group | Epithelialization | | | | | p value |
|------------------|----------------------|-----------------------|-----------------------|------------------|----------------|---------|
| | Wound edge thickness | Cell migration (<50%) | Cell migration (≥50%) | Excision closure | Keratinization | |
| Day 14 | | | | | | |
| Negative control | 4 (100%) | 0 (0.0%) | - | 0 (0.0%) | - | 0.007 |
| NaCl | 0 (0.0%) | 4 (100%) | - | 0 (0.0%) | - | |
| Vaseline | 1 (20%) | 4 (80%) | - | 0 (0.0%) | - | |
| Ambergris | 0 (0.0%) | 3 (60%) | - | 2 (40%) | - | |
| Day 21 | | | | | | |
| Negative control | 4 (100%) | 0 (0.0%) | 0 (0.0%) | 0 (0.0%) | - | 0.007 |
| NaCl | 0 (0.0%) | 3 (100%) | 0 (0.0%) | 0 (0.0%) | - | |
| Vaseline | 0 (0.0%) | 2 (40%) | 0 (0.0%) | 3 (60%) | - | |
| Ambergris | 0 (0.0%) | 0 (0.0%) | 1 (25%) | 3 (75%) | - | |

*Kolmogorov-Smirnov test, significant p value <0.05.

On the 14th day, it was observed that 100% of the negative control group showed an epithelialization process, namely thickening of the wound edges. In the group of 2nd degree burns that were given vaseline, the epithelialization process showed thickening of the wound edges by 20% and 80% of the cells were moving <50%. In the 2nd degree burn group that was given 0.9% NaCl, 100% experienced an epithelialization process of <50% cell movement, while in the 2nd degree burns that were given Phytoster macrocephalus ambergris oil showed a cell movement process of <50% and 60 % experienced closure. excision of 40%. Based on the analysis, there was a difference in the epithelialization process between groups on day 14 which was statistically significant with a value of p=0.007. A microscopic view of the histology of the epithelialization process between groups on day 14 can be seen in the Figure 1.

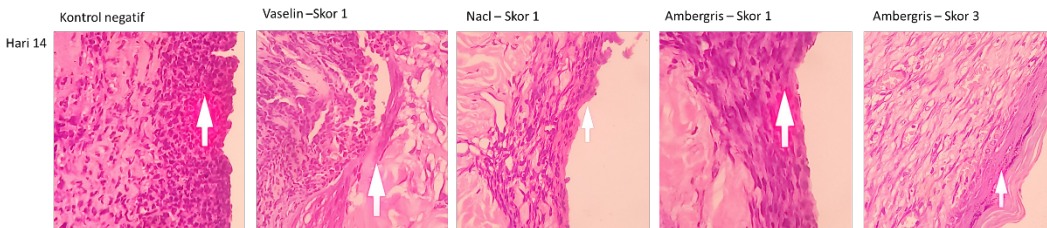


Figure 1.Microscopic photo of epithelialization on the 14th day

On the 21st day, it was observed that 100% of the negative control group showed an epithelialization process, namely thickening of the wound edges. In the group of 2nd degree burns that were given vaseline, 40% of the epithelialization process of <50% cell displacement occurred and 60% of the excisions closed. In the 2nd degree burn group that was given 0.9% NaCl, 100% experienced an epithelialization process of <50% cell movement, whereas in the 2nd degree burns that were given Phytoster macrocephalus ambergris oil, 25% showed a cell movement process of ≥50 % and experienced closure. excision of 75%. Based on the analysis, there was a difference in the epithelialization process between groups on day 21 which was statistically significant with a value of p=0.007. A microscopic view of the histology of the epithelialization process between groups on day 21 can be seen in the Figure 2

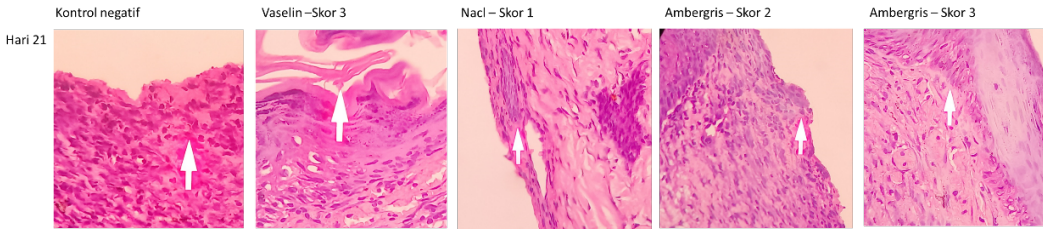


Figure 2.Microscopic photo of epithelialization on the 21st day

Next, the researchers wanted to know the location of the differences in epithelialization for each intervention group which are presented in the table 2.

Table 2.Comparison of interventions with the epithelialization process between groups

| Group | p-value | |
|-------------------------------|---------|---------|
| | Day-14 | Day -21 |
| Negative control vs Nacl | 0.029* | 0.057 |
| Negative control vs Vaseline | 0.063 | 0.016* |
| Negative control vs Ambergris | 0.016* | 0.029* |
| Nacl vs Vaseline | 0.730 | 0.250 |
| Nacl vs Ambergris | 0.413 | 0.057 |
| Vaseline vs Ambregris | 0.222 | 0.556 |

*Mann-Whitney test, significant p value <0.05.

In this study, there was a statistically significant difference in the epithelialization process between the negative control group compared to those given Nacl on the 14th day with a value of $p=0.029$, but no significant difference in the epithelialization process was found on the 21st day . There was no significant difference in the epithelialization process between the negative control group compared to those given vaseline on the 14th day, but a statistically significant difference in the epithelialization process was only found on the 21st day with ap value = 0.016.

There was a statistically significant difference in the epithelialization process between the negative control group compared to the administration of *Physeter macrocephalus ambergris* oil on the 14th day with a value of $p=0.016$ and on the 21st day with a value of $p=0.029$. However, there was no statistically significant difference in the epithelialization process between the administration of NaCl versus Vaseline, the administration of NaCl versus *Physeter macrocephalus ambergris* oil, and the administration of Vaseline versus *Physeter macrocephalus ambergris* oil with ap value > 0.05.

4. Discussion

Tissue damaged by burns will begin the wound healing process, which is the process of replacing damaged or necrotic tissue with new, healthy tissue. The phases of the wound healing process consist of coagulation, inflammation, proliferation and remodeling. The inflammatory phase is characterized by an abundance of inflammatory cells such as neutrophils. PMN cells are very important, especially when injury occurs, namely by increasing the number of PMN cells as a response to the movement of body cells or what is called chemotaxis produced by microorganisms. The proliferation and epithelialization stages are important components used as parameters to determine the success of wound healing. Re-epithelialization has a big influence on the wound healing process, because the faster the wound closes, the faster the re-epithelialization process, so the faster the wound healing process.^{6,7}

Based on the results of histopathological epithelialization research, it shows that second degree burns treated with *Physeter macrocephalus ambergris* oil showed a cell movement process of <50% as much as 60% and experienced 40% excision closure on the 14th day, while on the 21st day the process showed cell migration $\geq 50\%$ was 25% and excision closure was 75%. Apart from that, there was a significant difference in neutrophil cells in the group given *Physeter macrocephalus ambergris* oil with p value < 0.05 when compared with no treatment (negative control) at each phase of wound healing (days 14 and 21), it will be seen that the *Physeter macrocephalus ambergris* oil treatment group showed better results, indicating that there was an increase in epithelialization up to the stage of closing the excision on the 21st day; (negative control vs *Ambergris*, p value=0.016 Day-14 and p value=0.029 Day-21).^{8,9}

The results of the study are interesting when compared with the process of epithelialization of 2nd degree burns that were given NaCl solution, epithelialization was faster on the 14th day, statistically significant (negative control vs NaCl, p value = 0.029) compared to 2nd degree burns that were given vaseline, which experienced epithelialization on day 21 (negative control vs vaseline, p value = 0.016). Therefore, from these results it can be concluded that the epithelialization process in second degree burns treated with *Ambergris* oil was statistically and clinically significant on histology on the 14th day and also on the 21st day compared to not receiving any treatment.¹⁰

The results of this study showed that each group had the same effect on the epithelialization process of second degree burns, namely the epithelialization process was not statistically significant between the administration of NaCl vs. Vaseline, the administration of NaCl vs. *Physeter macrocephalus ambergris* oil, and the administration of Vaseline vs. *Physeter macrocephalus ambergris* oil. with p value > 0.05 on the 14th day and on the 21st finger. This means that *Ambergris* Oil has been proven to have the same effect as the wound epithelialization process if it is also given with Vaseline or NaCl solution. So based on these findings we can state that *Ambergris* Oil can be considered as one of the newest modalities that has an influence on the epithelialization process of burn wounds.¹¹

However, not a single piece of literature has been found regarding the use of *Physeter macrocephalus ambergris* oil for treating second degree burns. The overall therapeutic effect of *ambergris* is thought to be motivated by its bioactive contents such as ambrein, ambroxane, epi-Coprosterol and Coprostanone or flavonoids which can be found in almost all plants. medicine that has been explored to date. Catechin (flavan-3-ol), which is able to regulate the wound healing process, is one of the most researched flavonoids. Some researchers hypothesize that flavonoids such as apigenin can help treat skin injuries by limiting the release of inflammatory mediators thereby inhibiting the development of fibroblasts, because wound healing is hampered due to insufficient or excessive operation of fibroblasts.¹²

Re-epithelialization has a big influence on the wound healing process, because the faster the wound closes, the faster the re-epithelialization process, so the faster the wound healing process. In the first 24 hours an epithelialization process will occur which is characterized by thickening of the epidermis layer at the edges of the wound. Within a few hours after injury, re-epithelialization begins and the release of EGF (epidermal growth factor), TGF α (transforming growth factor α), and FGF (fibroblast growth factor) which acts to stimulate epithelial cell migration and proliferation. This process begins with the dissolution of cells and the cell substratum followed by polarization and migration of keratinocytes during the ECM. Once wound closure (100% epithelialization) is achieved, keratinocytes undergo stratification and differentiation to restore the barrier.^{13,14}

5. Conclusion

There are differences in the epithelialization of the wound closure process in second degree burns in experimental animal groups after topical administration of *Physeter macrocephalus ambergensis*. Ambergensis oil can be used as a new modality in the treatment of second degree burns. Further research needs to be carried out because the study topic that researchers are currently conducting is an exploratory, pilot and novel research concept. It is hoped that further research can develop research that is tested on humans, so that it can be developed and used for the wider community.

References

1. Schaefer TJ, Szymanski KD. Burn Evaluation and Management [Internet]. StatPearls [Internet]; 2022. Available from: <https://www.ncbi.nlm.nih.gov/books/NBK430741/>
2. Warby R, Maani CV. Burn Classification [Internet]. StatPearls [Internet]; 2022. Available from: <https://www.ncbi.nlm.nih.gov/books/NBK539773/>
3. Risal Wintoko ADNY. Current Management of Wound Care. *J Health Univ. Lampung*. 2020;4:183–9.
4. Centers for Disease Control and Prevention. Emergency Wound Care [Internet]. Disasters. 2023 [cited 2023 Aug 14]. Available from: <https://www.cdc.gov/disasters/woundcare.html>
5. Ousey K, Clinical A, Cutting KF, Perfectus C, Care W, Rogers AA, et al. The importance of hydration in wound healing: reinvigorating the clinical perspective. *J Wound Care*. 2016;25(3):122–30.
6. Markiewicz-Gospodarek A, Koziol M, Tobiasz M, Baj J, Radzikowska-Büchner E, Przekora A. Burn Wound Healing: Clinical Complications, Medical Care, Treatment, and Dressing Types: The Current State of Knowledge for Clinical Practice. *Int J Environ Res Public Health*. 2022;19(3).
7. Tiwari VK. Burn wounds: How it differs from other wounds. *Indian J Plast Surg*. 2012;45(2):364–73.
8. Pastar I, Stojadinovic O, Yin NC, Ramirez H, Nusbaum AG, Sawaya A, et al. Epithelialization in Wound Healing: A Comprehensive Review. *Adv Wound Care*. 2014;3(7):445–64.
9. de Araújo Pereira Venceslau SC, Ferreira JLS, Barros RMF, de Moraes RM, dos Santos HH, de Oliveira VMA, et al. Effects of photobiomodulation on re-epithelialization of burn wounds: protocol for a randomized controlled trial. *Trials* [Internet]. 2022;23(1):1–10. Available from: <https://doi.org/10.1186/s13063-022-06505-4>
10. Badruddeen PKS, Khan MI, Khalid M, Ghazanfer G. Potential Benefits of Ambergensis Beyond Perfume. *J Complement Med Altern Healthc*. 2018;7(1):8–10.
11. Hou Q, Li M, Lu YH, Liu DH, Li CC. Burn wound healing properties of asiaticoside and madecassoside. *Exp Ther Med*. 2016;12(3):1269–74.
12. The Editors of Encyclopedia Britannica. Ambergensis [Internet]. Science. 2023 [cited 2023 Aug 14]. Available from: <https://www.britannica.com/science/ambergensis>
13. Ambergensis Europe. Ambergensis [Internet]. Content. 2023 [cited 2023 Aug 14]. Available from: <https://ambergensis.eu/en/content/6-description-ambergensis>
14. Osterloff E. What is ambergensis? [Internet]. Oceans. 2023 [cited 2023 Aug 14]. Available from: <https://www.nhm.ac.uk/discover/what-is-ambergensis.html>