

# Saccular Pulmonary Aneurysm Mimicking a Pulmonary Mass: a Case Report

Gracia Dewitacita Tanaya<sup>1</sup>, Adisty Sari<sup>2</sup>, Sheila Gerhana Darmayanti<sup>3</sup>

Email: gracia.dtanaya@gmail.com

<sup>1</sup>BaliMed Buleleng Hospital, Bali, Indonesia, 60131

Department of Pulmonology and Respiratory Medicine, Buleleng Regency General Hospital, Bali, Indonesia, 60131

---

## Abstract

**Introduction:** Pulmonary artery aneurysm (PAA) is a rare disorder. The pathophysiology of PAA varies. Radiological modalities were very important due to atypical clinical manifestations. Diagnosis approach of PAA is very important to avoid miss diagnosis and miss treatment.

**Case:** A 51-year-old female patient came with chief complaints of shortness of breath since 5 years ago that was worsened 2 days before being admitted to emergency room. The complaints were felt throughout the day, that usually only appears if she did heavy activity due to history of chronic heart failure (CHF). Patient had a history of uncontrolled hypertension for years that leads to renal failure and CHF. A post pleural effusion evacuation Chest X-Ray evaluation revealed a well-defined but partially lobulated consolidation that is suspected as a lung mass. A CT scan with contrast showed a pulmonary aneurysm. A Doppler ultrasound revealed a pulmonary artery aneurysm showed by the turbulence of vascular flow. The patient got conservative oral therapy and monitoring for signs of aneurysm complications while waiting for the patient's agreement to be referred to tertiary hospital for CTPA (Computed Tomography Pulmonary Angiography) which is the gold standard on diagnosed PAA.

**Conclusion:** PAA is a rare cardiovascular disorder with atypical clinical manifestations. Radiological examinations such as Doppler ultrasound, Trans Thoracic Echocardiography and Computed Tomography could be done for diagnostic approach of PAA in the hospital with limitation of radiologic modality. Diagnosis of PAA should be considered in the differential diagnosis of a pulmonary nodule or mass.

*Keywords:* pulmonary artery aneurysm; pulmonary mass; diagnostic approach

---

## INTRODUCTION

Pulmonary artery aneurysm (PAA) is a rare pulmonary artery dilation disorder with an incidence rate of 1:13.696 case in the 109.571 autopsy study observed by Deterling and Clagett (1). There has been no report about the incidence of PAA in Indonesia (2). The pathophysiology of PAA varies. Atypical clinical manifestations and often appear as asymptomatic, implicate of the importance usage of radiological modalities. Imaging features of PAA on Chest X-Ray varies. PAA can be found as a small peripheral solitary nodule (3) or resemble as a large lung mass as found in this case report. Clinicians should be more

careful, especially before deciding to carry out interventional diagnostic procedures in PAA, because of its atypical clinical manifestations and radiological features as noted before. There are no clear management guidelines for this cardiovascular disorder yet, even though the morbidity and mortality rates due to rupture are very high (4). Diagnosis approach of PAA is very important because of the non-specific clinical manifestations that can lead to miss diagnosis and miss treatment which can lead to life-threatening complications (5).

## CASE PRESENTATION

A 51-year-old female patient came with chief complaints of shortness of breath since 5 years ago that was worsen 2 days before being admitted to emergency room. Shortness of breath was felt throughout the day, but usually the complaints only appears if she did heavy activity due to history of chronic heart failure. Shortness of breath getting worse, especially when the patient lies in a supine position. Complaint was getting better, when she was in a sitting position or lied to the right side. Patient also came with distended stomach that appeared since 2 days before being admitted to the emergency room. A history of edema in the legs was denied. She consumed 150-300 ml of mineral water a day. Daily urine output was very low due to history of ESRD (End Stage Renal Disease) since 6 years ago.

Patient had a history of uncontrolled hypertension (HT) for more than 15 years ago, since six years ago she start to complained the shortness of breath during heavy activities, the shortness of breath was getting worse every day and it came with the distended of abdomen, edema on the legs and very low urine production. The patient was diagnosed with ESRD (End Stage Renal Disease) and get routine hemodialysis twice a week (every Wednesday and Saturday) and CHF NYHA Class II caused by HHD (Hypertension Heart Disease) controlled by consuming oral anti hypertension (Amlodipine 1x10mg, V-block 1x6.25mg, Candesartan 1x16mg and Methyldopa 3x250mg).

The examination of vital signs showed blood pressure of 220/100 mmHg, pulse rate of 86 beats per minute with strong and regular pulse, respiratory rate of 30 times per minute, normal axillary temperature (36.8°C) and saturation of 89% (room air). Physical examination of the head and neck showed anemic conjunctiva and dyspnea. Physical examination of the lung and heart showed: (1) inspection: the space between the ribs of the right hemi thorax is widened and the movement of the right hemi thorax is left behind, (2) palpation: the trachea is in the middle, the movement of the right side of the chest is left behind when inspiration, the vocal fremitus was decrease on 2/3 lower part of right hemi thorax and also ictus cordis shifted to the left lateral (3) percussion: percussion sound was decrease on 2/3 lower part of right hemi thorax

(4) auscultation: minimal ronchi in both lungs, decreased vesicular sound on 2/3 lower part of right hemi thorax and no murmur found or gallops. Physical examination of the abdomen showed a positive undulation test. Physical examination of the extremities showed akral: warm, red and dry with no pitting edema.

Laboratory evaluation showed Hb (hemoglobin) of 7.7 g/dL (normal range: 12.0-16.0 g/dL) with MCV was 70.0 fL (normal range: 80.0-100.0 fL) and MCHC was 30.7 g/dL (normal range: 32.0-36.0 g/dL) - below normal and high renal function test included urea of 126.8 mg/dL (normal value: 6-20 mg/dL) and serum creatinine of 9.21 mg/dL (normal value: 0.60-1.10 mg/dL). Electrocardiography (ECG) evaluation showed a right ventricle hypertrophy (RVH). Chest X-ray anterior-posterior (AP) position evaluation showed cardiomegaly with interstitial lung edema, pocketed right pleural effusion with a suspect of lung mass and aortic atherosclerosis (**Fig. 1a**). Based on the anamnesis, physical examination, laboratories and radiologic findings, the patient was diagnosed with Hypertensive Emergencies, ESRD on Regular HD, ADHF (Acute Decompensated Heart Failure) profile B caused by HHD, right pleural effusion and microcytic hypochromic anemia. The patient got oxygenation therapy, intravenous diuretics and antihypertensive drugs and also hemodialysis as scheduled to stabilize his condition. Then she was admitted to the intensive care unit once her condition stabilized.

Three days later, 1100 cc of right hemi thorax pleural effusion was evacuated and pleural fluid analysis was done. Analysis of the pleural fluid showed a slightly cloudy yellowish with a leukocyte cell count of 292 cells per L (normal value: <1000 cells per L), leukocyte count predominant with a mononuclear cells which is 62% and polymorphonuclear cells (PMN) of 38%, total protein <50 % serum (protein ratio <0.5), glucose equal to serum, LDH (Lactate Dehydrogenase) <60% serum or <200 U/L, cholesterol <45 mg/dL and Rivalta negative The results of pleural effusion analysis concluded as a transudate. Chest X-Ray anterior-posterior (AP) evaluation after hemodialysis and pleural effusion evacuation is shown in (**Figure. 1b**) which shows a relatively well-defined but partially lobulated consolidation that is suspected as a lung mass. The patient denied any complaints of prolonged cough, hemoptoe, significant weight loss, history of malignancy, history of tumors, history of lymph node swelling on the head, neck and arms, history of long term smoking and history of exposure to carcinogenic substances. Physical examination of the lungs was evaluated again and showed: (1) inspection: symmetric chest wall movement, (2) palpation: trachea was in the middle, chest movement was symmetric during inspiration, vocal fremitus is slightly decreased on the 1/3 lower part of the right hemi thorax (3) percussion : percussion sound on 1/3 lower part of right hemi thorax was slightly decreased (4) auscultation: decrease of rhonchi sound on both lungs, vesicular sound slightly decreased on 1/3 lower part of right hemi thorax. There was no physical examination that suggested a lung mass (asymmetric chest movement, increase of vocal fremitus, percussion sound and vesicular sound on

auscultation).

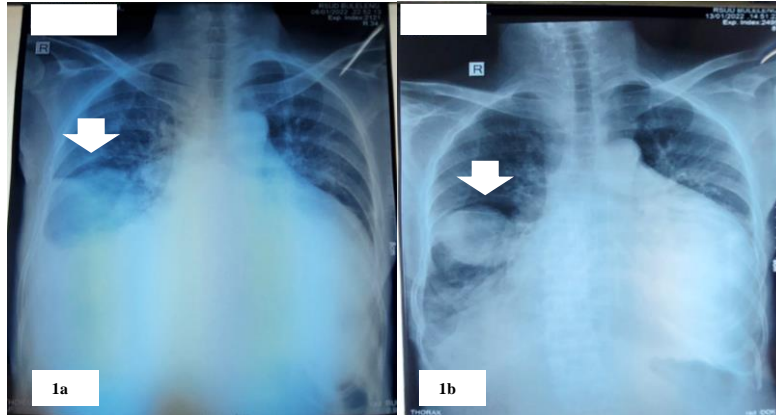


Figure 1a and 1b

A CT scan with contrast was performed to confirm diagnosis of pulmonary mass. It showed an enhancing isodens lesion (vascular like enhancing lesion) in the middle lobe of the right lung with size 4.42x3.56x4.35 cm, suspected as pulmonary aneurysm, right pleural effusion, cardiomegaly and aortic atherosclerosis (**Figure 2**). Meanwhile, a Doppler ultrasound concluded that there was a right pleural effusion with minimal left pleural effusion and the presence of a saccular type of right pulmonary artery aneurysm with size 5.26 x 4.71 cm which was showed by the 'yin and yang' sign which described the turbulence of vascular flow (**Figure 3**). The patient got conservative oral therapy and monitoring for signs of aneurysm complications while waiting for the patient's agreement to be referred to tertiary hospital for CTPA (Computed Tomography Pulmonary Angiography) which is the gold standard on diagnosed PAA.

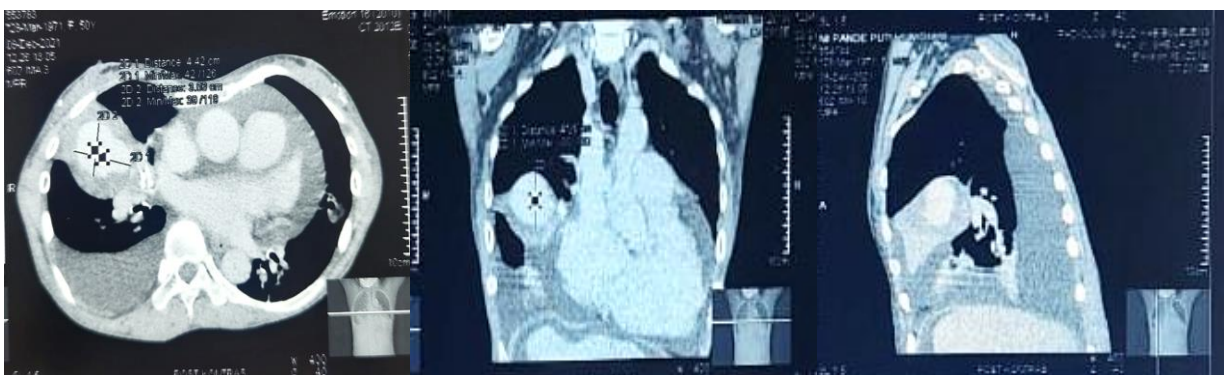

Figure 2

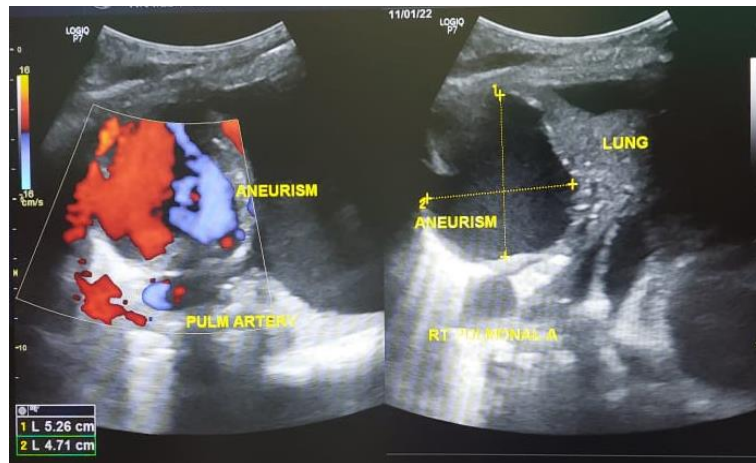


Figure 3

## DISCUSSION

A True PAA is defined as dilation of pulmonary arteries due to weakened elastin and collagen tissue that involved three layers of blood vessel walls (tunica intima, media and adventitia). While pseudo aneurysm does not involve all layers of the blood vessel wall (1,2). Pseudo aneurysm are more fragile so, more aggressive treatment will be needed because of the greater possibility of rupture. The mean diameter of the main pulmonary artery (MPA) in adults is  $25 \text{ mm} \pm 3 \text{ mm}$  with a normal upper limit of 29 mm in men and 27 mm in women (6). While the literature review study by Theodoropoulos et al., generalizes the normal upper limit of the MPA diameter of 29 mm. The diameter of the right interlobary artery is 17mm (7). Widening of the MPA diameter above the normal value is defined as enlargement of the MPA, whereas PAA occurs when the MPA diameter is 1.5 times the upper limit of the normal value (43 mm in males and 40 mm in females) (6). Another study states, PAA occurs when the MPA diameter is more than 45 mm and the interlobary artery diameter is more than 30 mm (8).

Based on their location, PAA can be classified into proximal and peripheral PAA. The proximal PAA involves the pulmonary trunk, left and/or right main pulmonary arteries. According to Yusup and Nguyen, the mechanism of PAA can be summarized into 4 mechanisms, such as connective tissue damage, inflammation, calcification and thrombus formation and also genetics. A weak connective tissue between the three layers of blood vessel walls triggers dilation of blood vessels or aneurysms. Metalloproteinase Proteinases enzymes (MMP) and cysteine protease enzymes (including cathepsins K, L and S) which have elastolytic and collagenolytic properties play an important role in this process. Damage to connective tissue will be followed by the release of inflammatory factors (VEGF or Vascular Endothelial Growth Factor and TGF- $\beta$  or

transforming growth factor  $-\beta$ ) that causes the continuity of inflammatory process. Trauma can be another mechanism that can cause damage to the connective tissue of blood vessel walls. Macrophages and lymphocytes are the predominant cells histologically on an aneurysms. These two cells will trigger a pro-inflammatory cytokine cascade that activates a protease (CD 69, CD 25, CD 38 and CD 45RO). Pro-inflammatory cytokines (IL-1 $\beta$ , TNF alpha, IL-6, IL-8, MCP-1, IFN- $\gamma$ , and GM-CSF) have been known could activate c-Jun N-terminal kinase (JNK) in smooth muscle cells which triggers the secretion of MMPs and other inflammatory cytokines. The discovery of T lymphocytes, B lymphocytes and dendritic cells in the tunica adventitia indicates a chronic inflammatory process in the aneurysm. Meanwhile, calcification and thrombus can increase the pressure on the vessel wall, triggering turbulence in flow and accelerating the process of aneurysm formation and increasing the risk of aneurysm rupture. Genetic disorders such as Ehler-Danlos syndrome and Marfan syndrome are also known to cause weakening of the connective tissue in the walls of blood vessels (2,9).

PAA rarely causes symptoms and it's often diagnosed incidentally. Physical examination in PAA cases was not specific. The symptoms (coughing blood, shortness of breath, chest pain, palpitations and syncope episodes) caused by complications due to its compression effects on surrounding structures such as large airways and coronary arteries, rupture, dissection, thrombosis and pulmonary valve regurgitation (4,7). Symptoms of compression such as shortness of breath, cough with or without blood and chest pain are very common in people with pulmonary mass or tumor. The symptoms of pulmonary mass were chronic progressive (10). Patients with pulmonary mass also experience significant weight loss, due to an increase in resting energy expenditure which results in hyper metabolism. Patients with non-small-cell lung cancer (NSCLC), weight loss caused by an increase in inflammatory mediators and acute phase protein secretion (11). A history of long term smoking, exposure to carcinogenic substances or radiation, cancer in the patient itself or on their family are an important medical and social history on pulmonary mass diagnosis (10).

Physical examination and signs that can be found on patient with pulmonary mass is very depending on the location, size of the tumor and its location of metastasis. In pulmonary mass, physical examination showed: 1) inspection: chest wall movement is left behind, 2) palpation: deviation of trachea the normal side due to mass to mass compression effect, chest movement may left behind when inspiration phase, vocal fremitus increases, 3) percussion: increase of percussion sound and 4) auscultation: increased of vesicular sound (12). Other physical examination findings (signs of mass regional growth) can be showed as enlargement of lymph nodes and neurological disorders, metastases, venectasis or enlargement of the veins followed by edema of the face, neck and arms (superior vena cava syndrome) or edema accompanied by pain

in the limbs called Deep Vein Thrombosis (DVT) (10).

In our case, the right PAA (proximal PAA) with size >4cm did not cause clinical manifestations. The symptoms of shortness of breath did not caused by PAA compression in the airway. It was caused by pleural effusion and ADHF (overload syndrome) due to ESRD. This clinical manifestation supported by the results of pleural effusion analysis which is interpreted as a transudate (effusion fluid with low protein content caused by an imbalance of hydrostatic or osmotic pressure). Whereas in lung masses (malignancy) exudate type effusion is caused by increased capillary permeability which indicates pleural involvement in the inflammatory process or malignancy itself (13).

ESRD patients experience water and sodium retention which causes overload syndrome. Overload syndrome will increase blood flow to the left ventricle, which will chronically lead to left ventricular decompensation (LVH). This will trigger pulmonary venous hypertension (venous PH) causing pulmonary venous congestion and pulmonary congestion that lead to increasement the work of the right heart (14,15). The ESRD-LVH-PH relationship is summarized in (Figure 4).

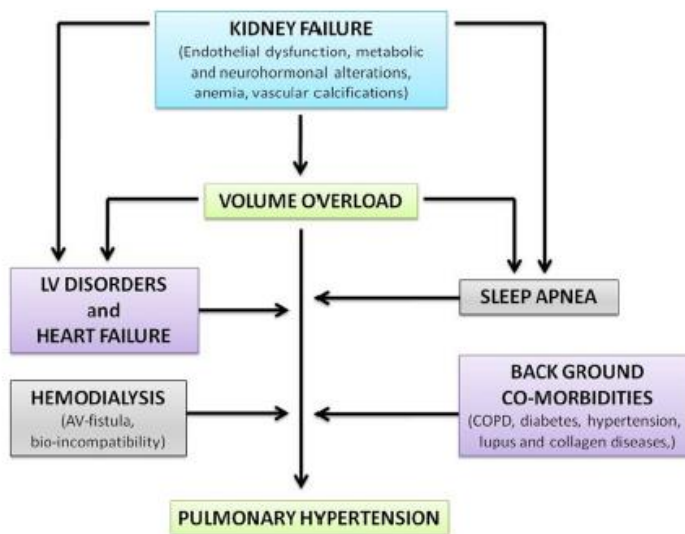


Figure 4

Our case showed RVH on ECG, cardiomegaly on chest X-ray and enlargement of all cardiac chambers on thorax CT scan. According to Theodoropoulos et al., 66% of patients with PAA had PH, of which 81% had serious complications (PAA rupture) (7). The gold standard examination for diagnosing PH is RHC (Right

Heart Catheterization) by measuring pulmonary arterial pressure at rest (normal value 10 mmHg) and during exercise (normal value 30 mmHg) (4). PH as the etiology of PAA in this study could not be established due to limited radiology modality. A non-invasive examination that can be used as a diagnostic approach on suspected PH is MSCT (Multi Slice Computed Tomography) that showed dilatation of the right ventricle, right atrium, and pulmonary artery dilation (diameter  $\geq 1.29$  mm), or a ratio between the diameters of the pulmonary artery over ascending aorta  $\geq 1.1$ (16). Another study combined MSCT examination with the same criteria and TTE with criteria of TR (Tricuspid Regurgitatio) velocity  $>3.4$ m/s (4). Our patient full filled suspected PH criteria by PERKI.

Other acquired etiology of PAA such as infection (Tuberculosis and Syphilis) and trauma can be ruled out. Pulmonary TB secondary PAA known as Ramussen Aneurysm was typically located in the upper lobe of the lung. It occurs due to reactivation of pulmonary TB in that area. While PAA due to pyogenic bacterial and fungal infections is usually found in immunodeficiency patients or drug users (drug abused) which is often accompanied by endocarditis and septic embolism. Several medical procedures such as the use of a Swan-Ganz catheter, conventional angiography, surgical resection and biopsy can cause trauma that weakens the pulmonary artery wall which will facilitate the formation of aneurysms (iatrogenic) (2,9).

In addition to infection and trauma, acquired PAA is also as a result of vasculitis and neoplasms. Bechet and Hughes-Stovin syndromes are closely associated with the vasculitis underlying PAA. Bechet's syndrome is characterized by chronic vasculitis manifesting as oral and genital ulcers, usually accompanied by uveitis. PAA predilection in this syndrome is in the lower lobe of the lung accompanied by thrombosis and inflammation in the area around the PAA. Meanwhile, Hughes-Stovin syndrome is usually characterized by recurrent thrombophlebitis. Both primary and metastatic lung neoplasms can underlie the emergence of PAA due to the infiltration of neoplastic cells in the walls of blood vessels that triggers dilation of blood vessels. Other etiologies such as cardiac structural abnormalities with the highest prevalence of congenital abnormalities was Patent Ductus Arteriosus (PDA). Classification of intramural, atherosclerosis and chronic pulmonary hypertension caused by increased cardiac blood flow due to congenital structural abnormalities can result in a left to right shunt which will increase pulmonary artery pressure thereby facilitating the formation of aneurysms (2,9). Meanwhile, other etiologies which include cardiac structural abnormalities with the highest prevalence of congenital abnormalities-Patent Ductus Arteriosus (PDA) and vascular structural abnormalities with the highest prevalence on acquired disorders including medionecrosis, atherosclerosis, Marfan syndrome and vasculitis should be ruled out in our case using TTE (Trans Thoracic Ecocardiogram) (4,6). The etiology of PAA may be idiopathic if it full filled several criteria including: absence of abnormal intra or extra cardiac shunt, simple dilatation of the pulmonary trunk, absence of arterial disease and absence

of chronic cardiac or pulmonary disease (4).

The gold standard examination for diagnosing PAA is CTPA because of its ability to assess right-sided heart chamber pressure gradient and assess PAA expansion in surrounding vascular structures (4). Other PAA diagnostic approach are using CT scan with contrast (especially MSCT) and Color Doppler ultrasound (2) as seen in our case. Chest X-Ray examination could not distinguish between lung mass and PAA. Until now, there are no clear management guidelines for PAA. Several studies have shown that PAA patients with suspected PH have a greater risk of rupture complications, surgical therapy is considered to increase the patient's survival rate (4). Due to limited resources and unclear management guidelines, in our case (patient with suspected PH caused by ESRD), conservative therapy was given for optimizing the reducing of vascular pressure such as oral diuretics, oral antihypertensive drugs, hemodialysis (16) and also monitoring symptoms that occurred due to complications. Gupta et al., in their literature review study concluded the diagnostic and management approach of PAA which can be seen in **(Figure 5)** (6).

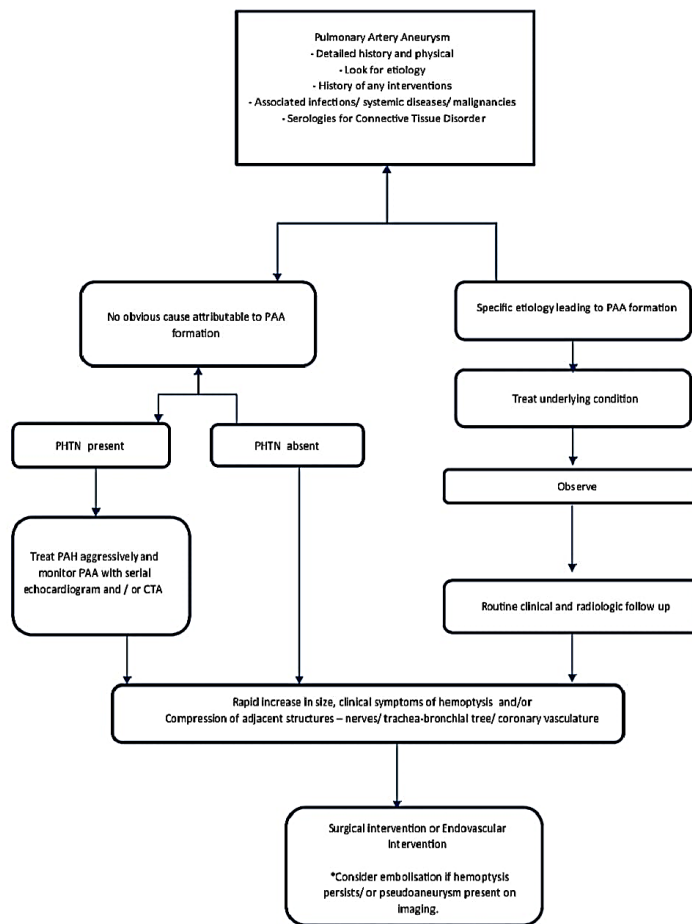


Figure 5

## CONCLUSION

PAA is a rare cardiovascular disorder with atypical clinical manifestations. The appearance of an aneurysm on chest X-ray may resemble a nodule or lung mass. Other radiological examinations such as Doppler ultrasound, TTE and CT scan (especially MSCT) could be done for diagnostic approach of PAA in the hospital with limitation of radiologic modality. A good history taking and physical examination can help to rule out the differential diagnosis. The diagnosis of PAA should be considered in the differential diagnosis of a pulmonary nodule or mass.

## ACKNOWLEDGEMENTS

None declared.

## REFERENCES

1. Deterling RA Jr and Clagett OT. Aneurysm of the pulmonary artery; review of the literature and report of a case. *Am Heart J* 1947; 34: 471–499.
2. Yusup I. STUDI KASUS ANEURISMA ARTERI PULMONALIS. *Jurnal Medika Malahayati*. 2020;4(2):146-153.
3. Kayhan S, Şahin Ü, Oğullar S. An Asymptomatic Saccular Aneurysm of Pulmonary Artery: A Rare Case of Solitary Pulmonary Nodule. *Annals of Clinical and Analytical Medicine*. 2015;06(06).
4. Intan R, Hasibuan F, Nugraha R, Octora T, Alkaff F. Proximal Pulmonary Artery Aneurysm Secondary to Suspected Pulmonary Hypertension Treated with Conservative Therapy in Limited Resource Setting. *American Journal of Case Reports*. 2019;20:1805-1811.
5. Ahmed K, Javed A, Pervez M, Fatima S, Fatimi S. LEFT PULMONARY ARTERY ANEURYSM SECONDARY TO METASTATIC LUNG SARCOMA: A CASE REPORT. *Chest*. 2020;157(6):A262.
6. Gupta M, Agrawal A, Iakovou A, Cohen S, Shah R, Talwar A. Pulmonary artery aneurysm: a review. *Pulmonary Circulation*. 2020;10(1):1-10.
7. Theodoropoulos P, Ziganshin B, Tranquilli M, Elefteriades J. Pulmonary Artery Aneurysms: Four Case Reports and Literature Review. *International Journal of Angiology*. 2013;22(03):143-148.
8. Restrepo CS and Carswell AP. Aneurysms and pseudoaneurysms of the pulmonary vasculature. *Semin Ultrasound CT MR* 2012; 33: 552–566.
9. Nguyen, E. T., Silva, C. I., Seely, J. M., Chong, S., Lee, K. S., & Müller, N. L. (2007). Pulmonary artery aneurysms and pseudoaneurysms in adults: findings at CT and radiography. *AJR. American journal of roentgenology*, 188(2),W126–W134.
10. Komite Penanggulangan Kanker Nasional. *Panduan Penatalaksanaan Kanker Paru*. Jakarta: Kementerian Kesehatan Republik Indonesia; 2022. p1-31.
11. Ross P, Ashley S, Norton A, Priest K, Waters J, Eisen T et al. Do patients with weight loss have a worse outcome when undergoing chemotherapy for lung cancers?. *British Journal of Cancer*. 2004;90(10):1905-1911.

12. Hariadi S, Amin M, Jusuf Wibisono M, Hasan H. Dasar-Dasar Diagnostik Fisik Paru. 4th ed. Surabaya: Departemen Pulmonologi dan Kedokteran Respirasi Fakultas Kedokteran Universitas Airlangga; 2012. p25-41.
13. Wande, I Nyoman. Buku Interpretasi Analisa Cairan Pleura. 1<sup>st</sup> ed. Denpasar: Departemen Patologi Klinik Universitas Udayana; 2016. p1-14.
14. Wanner C, Herzog C, Turakhia M, Blankestijn P, Carrero J, Clase C et al. Chronic kidney disease and arrhythmias: highlights from a Kidney Disease: Improving Global Outcomes (KDIGO) Controversies Conference. *Kidney International*. 2018;94(2):231-234.
15. Bolignano D, Rastelli S, Agarwal R, Fliser D, Massy Z, Ortiz A et al. Pulmonary Hypertension in CKD. *AJKD*. 2013;61(4):612-622.
16. PERKI. Pedoman Diagnostik dan Tatalaksana Hipertensi Pulmonal. 1<sup>st</sup> ed. Jakarta:PERKI; 2021.p1-105.