

# The role of Teriparatide in post-thyroidectomy permanent hypoparathyroidism: A case report

Deasy Natalia Adriana<sup>a</sup>, Agung Pranoto<sup>b\*</sup>

<sup>a</sup>Department of Internal Medicine, Faculty of Medicine, Dr. Soetomo Teaching Hospital, Universitas Airlangga, Surabaya, East Java, 60286, Indonesia

<sup>b\*</sup>Division of Endocrinology and Metabolic Disease, Faculty of Medicine, Dr. Soetomo Teaching Hospital, Universitas Airlangga, Surabaya, East Java, 60286, Indonesia. Email for corresponding author: agung-p@fk.unair.ac.id

---

## Abstract

Hypoparathyroidism is a rare endocrine disease that is commonly found following anterior neck surgery. The case of permanent hypoparathyroidism occurring years after surgery is even more exceptional; therefore, it is highly potential to be left undiagnosed and thus untreated. The goal of treatment in hypoparathyroidism is to maintain the blood calcium level near the low end of the normal range while preventing symptoms of hypocalcemia. The most recent treatment also includes parathyroid hormone therapy. We present a case of a 63-year-old male presenting with vertebral fracture as a complication of hypoparathyroidism diagnosed 3 years after total thyroidectomy. He also had chronic hypocalcemia refractory to calcium and active Vitamin D supplementary. The patient was then treated with routine subcutaneous Teriparatide injection with a satisfying outcome. Serum calcium level was maintained within normal range and other symptoms of hypocalcemia resolved.

*Keywords:* hypoparathyroidism; fracture; hypocalcemia; teriparatide

---

## 1. Introduction

Hypoparathyroidism is a rare disorder of parathyroid hormone (PTH) deficiency, with an estimated prevalence of 23 to 37 per 100,000 persons per year. Anterior neck surgery is the most common etiology of hypoparathyroidism (in approximately 78% of cases). Therefore, this disease is seen more frequently in older adult women, who are more likely than others to undergo thyroid surgery (1,2). The true incidence of postoperative hypoparathyroidism however remains debatable due to significant heterogeneity in how it has been studied (3).

Hypoparathyroidism is characterized by hypocalcemia, hyperphosphatemia, and a low or inappropriately normal serum parathyroid hormone (PTH) level (4). Transient hypoparathyroidism is defined as when the condition arises less than 6 months after surgery, while permanent hypoparathyroidism continues beyond 6 months after surgery (5). Postoperative hypoparathyroidism is the most common and often the most troubling long-term consequence of aggressive thyroid surgery (6). Hence clear medical indications of central/anterior neck surgery along with information of postoperative complications are mandatory.

Most signs and symptoms of hypoparathyroidism are the results of hypocalcemia since low serum ionized calcium can alter neurological, cognitive, muscular, and cardiac function (7). Hypoparathyroidism is also associated with markedly reduced bone remodelling (8). The long-term effects of increased bone mass and low

---

bone turnover (possibly deleterious to bone quality) on bone strength and fracture risk remain unclear (5,9). Nevertheless, the data on fracture risk among patients with this disorder vary. In some postoperative hypoparathyroidism cohorts, patients may have a decreased risk of fracture in the upper extremities, whereas others have had an increased risk of vertebral fractures despite having normal or increased bone mineral density (1,10).

The goal of managing hypoparathyroidism, potential or actual, is to avoid the symptoms and complications of hypocalcemia (3). This is usually achieved with oral calcium and active vitamin D supplementation but may involve treatment with subcutaneous parathyroid hormone therapy. Many studies have furthermore shown that hypocalcemia can be adequately managed in most patients by means of once-daily or twice-daily subcutaneous injections of teriparatide (PTH 1-34 fragment) or human recombinant PTH (rhPTH 1-84) (11). Here we report a case of a patient with hypoparathyroidism as a complication of anterior neck surgery presenting with vertebral fractures and managed with teriparatide.

## 2. Case

A 63-year-old male was referred from an orthopedist to our endocrinology clinic due to pathologic vertebral fracture along with hypocalcemia and previous history of total thyroidectomy. The patient came to the orthopedist with back pain as the chief complaint. Back pain rose especially at the beginning of movement, such as standing up from a sitting position. He was however still able to do daily activities without assistance. The patient denied any history of trauma prior to complaint. He also reported some other complaints such as general fatigue, lack of focus, mild paresthesia in both lower extremities, and infrequent muscle cramp for about a year. The patient however denied any history of seizure, dyspnea, and decreased visual ability. He furthermore admitted a history of thyroid surgery 3 years earlier. The patient at that time presented himself with an enlarged mass around 5 cm in size on the anterior neck recognized around a month earlier. The patient denied any history of oral thyroid medication prior to surgery. Post-surgical pathology anatomy showed adenomatous goiter as result. The patient remained asymptomatic after surgery and was then evaluated for thyroid function monthly after surgery and revealed hypothyroid. The patient was then treated with Levothyroxine with a dose ranging from 50-150 mg and the TSHs level varied from 0.475  $\mu\text{IU}/\text{ml}$  to 3.379  $\mu\text{IU}/\text{ml}$ . Figure 1 shows the patient's clinical condition and post-thyroidectomy pathology result.

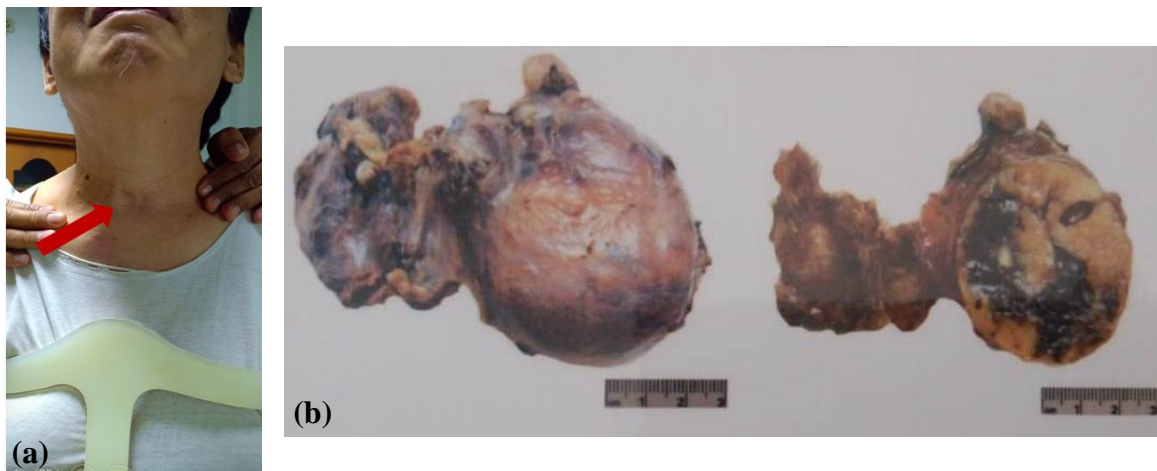

Fig.1. (a) Clinical condition of the patient wearing lumbar support to secure the spine. Arrow in picture exposes the thyroidectomy surgical mark; (b) Pathology anatomy result from previous thyroidectomy revealed an adenomatous goiter.

We then proceeded with specific laboratory and radiologic examinations with results as follows. Patient's blood routine evaluation revealed normal with Hgb 13.5, Hct 38.3%, Wbc 10,100, Neutrophil 73.9%, Lymphocyte 13.4%, Platelets 344,000. His electrolyte serum levels revealed normal, except for his low serum calcium 7.7 mg/dl (8.6-10.3 mg/dl). The phosphate and magnesium serum levels were within normal limits as 3.6 mg/dl (3.4-4.5 mg/dl) and 2 mg/dl (1.7-2.2 mg/dl), respectively. Interestingly, his intact parathyroid level which had never been evaluated before revealed low 9.5 pg/ml. Thyroid functions from TSHs 4.148  $\mu$ IU/ml (0.55-4.78  $\mu$ IU/ml) and FT4 1.18 ng/dl (0.89-1.76 ng/dl) were within normal range. We additionally searched for the patient's serum calcium level from the preceding year and discovered chronic hypocalcemia with results ranging from 7.4 to 7.6 mg/dl despite long treatment of 500 mg calcium lactate and 0.5 mg calcitriol. Magnetic resonance imaging (MRI) thoracolumbar showed compression fracture in second lumbar (L2) with 40% canal encroachment associated with focal diffuse bone marrow edema as seen in Figure 2. Abdominal ultrasound only showed a simple renal cyst without signs of nephrocalcinosis, kidney stones, or chronic parenchymal kidney disease. Electrocardiography and echocardiography results also revealed normal with no signs of cardiac arrhythmias or cardiomyopathy.

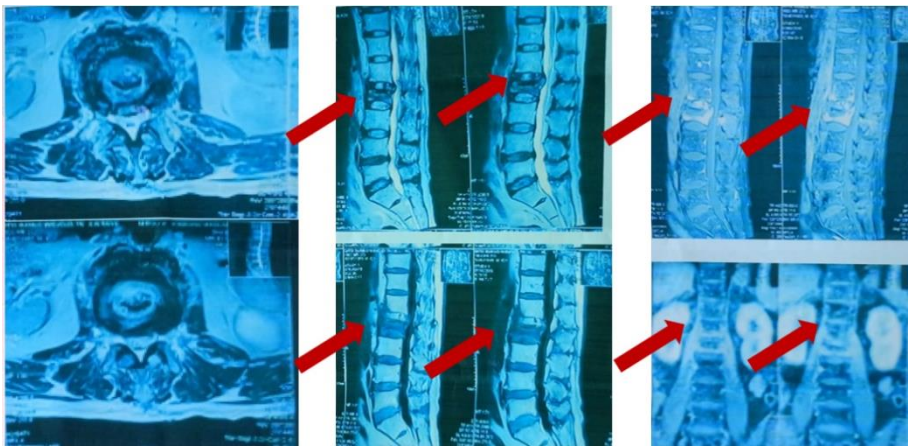


Fig.2. MRI Thoracolumbar. Arrows are showing compression fracture in second lumbar with 40% canal encroachment associated with focal diffuse bone marrow edema.

We assessed the patient with post-thyroidectomy permanent hypoparathyroidism, chronic hypocalcemia, compression fracture L2, and post-surgical hypothyroidism. The patient then underwent a stabilization for his surgery and was treated with Calcitriol 0.5 mg per oral two times daily and Teriparatide subcutaneous injection 20 mcg daily along with Levothyroxine to maintain his thyroid functions level. The patient's serum calcium level was maintained within a normal range up until around a year following routine Teriparatide injection (as seen in Figure 3) and hypocalcemia symptoms gradually resolved.

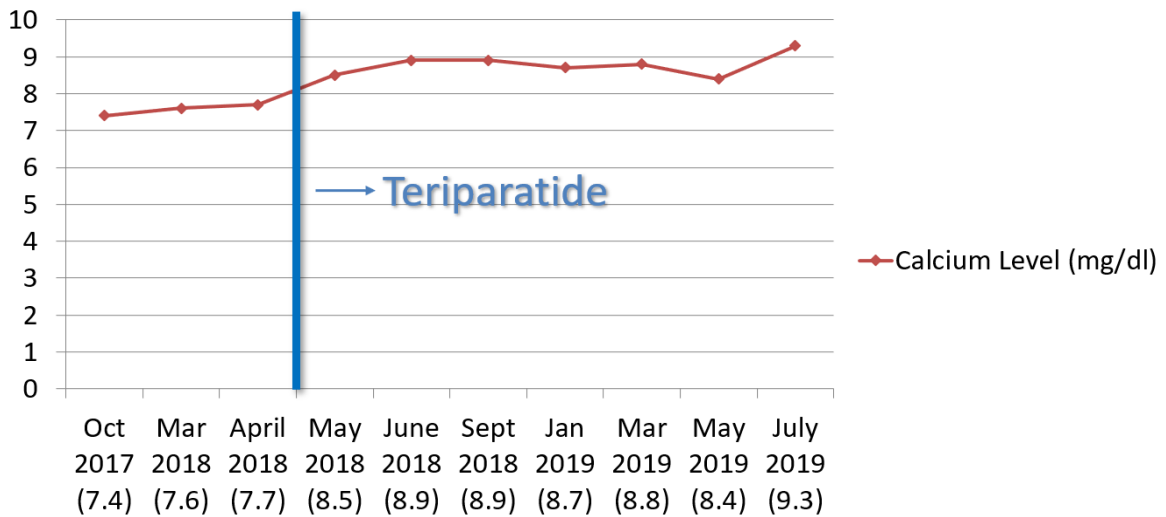


Fig.3. Trend of serum calcium level before and after treated with Teriparatide. Recorded serum calcium levels before given Teriparatide were below normal limit. Teriparatide injection was started in April 2018. Normal range for calcium serum: 8.6-10.3 mg/dl.

### 3. Discussion

Hypoparathyroidism is a rare endocrine disease with low calcium and inappropriately low or insufficient circulating parathyroid hormone levels (4,12). In patients with a history of thyroid, parathyroid, laryngeal or other neck surgeries, the temporal proximity of the surgical procedure to the development of hypocalcemia will determine whether this is acute and/or transient hypoparathyroidism (surgery <6 months prior) or chronic and permanent hypoparathyroidism (surgery >6 months prior) (5,7). Hypocalcemia for six months or more after surgery in the presence of a low or inappropriately normal PTH is diagnostic of permanent surgical hypoparathyroidism (4). In this patient, the hypocalcemia was found around two years following surgery with the calcium level recorded during 2017-2018 were 7.4, 7.6, and 7.7 mg/dl respectively. The intact PTH level two years after surgery appeared low on the level of 9.5 pg/ml.

The most common cause of hypoparathyroidism is neck surgery, during which parathyroid glands are inadvertently injured, removed, or deprived of their blood supply. The manipulation of parathyroid glands, even without their removal, can lead to transient disruption of parathyroid hormone production and/or release. Given the short half-life of PTH (3-5 minutes), even a temporary drop in output might lead to at least transient hypoparathyroidism with associated hypocalcemia, hypomagnesemia, and hyperphosphatemia. Manipulation of the parathyroid glands in both thyroid beds is precisely the background of most iatrogenic hypoparathyroidism. Thus, bilateral central neck operations, including total thyroidectomy (as seen in this patient), bilateral central neck dissection, and total laryngectomy can be followed by hypoparathyroidism even when the parathyroid glands are identified and preserved (6). Therefore, post-surgical close monitoring of calcium and PTH levels is indicated in order to identify hypoparathyroidism before the development of severe, symptomatic hypocalcemia. Rarely, hypocalcemia can develop years after surgery as occurred in our patient (1).

PTH along with vitamin D is the major hormonal regulator of calcium homeostasis in the human body. PTH achieves this by direct effects on the kidney and bone. PTH also affects calcium homeostasis by its indirect effects on the gastrointestinal tract through the production of activated Vitamin D 1,25OH in the kidney. PTH

secretion is controlled by the calcium-sensing receptor (CaSR) which is located on parathyroid cells and on renal tubules. PTH is secreted and increases calcium availability in the body. When the CaSR is stimulated by a low calcium level, PTH facilitates vitamin D 1,25OH production by the kidney, which leads to increased intestinal calcium absorption. Furthermore, PTH also stimulates renal tubular calcium reabsorption and phosphate excretion by the kidney. When the PTH secretion is inadequate or absent, hypocalcemia and hyperphosphatemia develop and represent the hallmark electrolyte abnormalities of this disorder (13).

The clinical manifestations of hypoparathyroidism are variable and can involve almost any organ system. The classic symptom of hypoparathyroidism is neuromuscular irritability owing to hypocalcemia (2,5). Clinical manifestations of hypoparathyroidism in the central nervous system include seizures, calcifications, and Parkinsonism or dystonia; neuropsychiatric system include symptoms of anxiety and depression; ophthalmological system include cataracts and papilledema; dental system might reveal altered tooth morphology; dermatological system manifestation include dry skin, onycholysis, coarse, thin hair, pustular psoriasis; musculoskeletal system might present with myopathy and spondyloarthropathy; paraesthesia, muscle cramp, and tetany might present in the peripheral nervous system; a manifestation in the renal system might include nephrocalcinosis, kidney stones, chronic kidney disease; laryngospasm might appear as a manifestation in the respiratory system; meanwhile cardiovascular system manifestation might occur as cardiac arrhythmias and hypocalcemia-associated dilated cardiomyopathy (9).

In the evaluation of the patient, we found reports of general fatigue, lack of focus, mild paraesthesia in both lower extremities, and infrequent muscle cramp. Abdominal ultrasound of the patient however only showed simple renal cyst with no signs of nephrocalcinosis, kidney stones, or chronic parenchymal kidney disease. Electrocardiogram evaluation also revealed normal with no signs of cardiac arrhythmias. Echocardiography results appeared with normal dimensions of all cardiac chambers and normal diastolic and systolic function.

Another noteworthy point from this case is the patient's pathologic vertebral fracture. Hypoparathyroidism is related to low bone turnover (the process of coupled bone formation and bone resorption), which is associated with increased bone mineral density but on the other hand, led to abnormal bone microarchitecture. The reduction in bone formation is demonstrated by the decrease of tetracycline labelling in bone biopsies compared with controls. Nevertheless, fracture risk in hypoparathyroidism is indefinite. Case-control studies demonstrate no differences in overall hypoparathyroidism fracture rates, while other reports show an increased fracture risk at the spine and upper extremities (14). Despite increased bone mass, bone fragility might exist in hypoparathyroidism because of deficits in bone material properties. Higher PTH levels might be associated with improved bone material strength, meanwhile in hypoparathyroidism patient's resistance to microfracture is decreased and might be associated with parameters of more pronounced disease (15).

The goal of treatment in hypoparathyroidism is to maintain the blood calcium level near the low end of the normal range while preventing symptoms of hypocalcemia; this is usually achieved by giving oral calcium and vitamin D supplementation. Calcium carbonate tablets that contain 40% by weight elemental calcium, for example, are considered economical and widely available. Since PTH is needed for activation of renal 25-hydroxyvitamin D 1 $\alpha$  hydroxylase, vitamin D analogues that have already undergone 1 $\alpha$ -hydroxylation (calcitriol and alfacalcidol) are generally preferred; these have a relatively short half-life as compared with other vitamin D analogues, thus decreasing the risk of prolonged hypercalcemia if vitamin D intoxication occurs (2). In contrast to most hormone deficiencies, in which hormone replacement is the mainstay of therapy, only recently the management of hypoparathyroidism may also involve injection with subcutaneous parathyroid hormone therapy. Standard therapy for hypoparathyroidism includes emergency management of hypocalcemia and also long-term management. However, conventional management of this disease in an extensive period is frequently related to hypercalciuria, nephrocalcinosis, nephrolithiasis, and renal insufficiency, thus emphasizing the need for careful monitoring and improved therapies (1).

As previously explained, the latest therapy in hypoparathyroidism includes the replacement of parathyroid hormone therapy. rhPTH 1-84 has been approved for the treatment of hypoparathyroidism that is refractory to conventional therapy in both the United States and (conditionally) in Europe. Many studies have shown that

hypocalcemia can be effectively managed by giving once-daily or twice-daily subcutaneous injections of teriparatide (PTH 1-34 fragment) or rhPTH 1-84 (16). Intermittent subcutaneous PTH therapy was able to stimulate bone turnover which had been found to be low in hypoparathyroidism, with bone turnover often still elevated above the normal range several years into treatment. PTH therapy has differential effects on skeletal compartments, with anabolic effects on trabecular bone and catabolic effects on cortical bone (8). Small case series involving patients who were treated with PTH 1-34 (for 18 months) or rhPTH 1-84 (for 8 years) have shown increased cancellous bone volume, trabecular number, and cortical porosity. Our patient received a once-daily subcutaneous injection of 20 µg teriparatide. The calcium levels after treatment improved along with the patient's clinical condition. Given the high bone turnover that is induced by PTH treatment, the discontinuation of PTH 1-34 therapy should be done gradually, with frequent monitoring and concomitant administration of higher than pre-PTH therapy doses of calcium and calcitriol to prevent severe hypocalcemia as the bone returns to a low-turnover state, similar to the hungry bone syndrome that is seen after parathyroidectomy in patients with hyperparathyroidism (11,17). Both PTH 1-34 and rhPTH 1-84 have the risk of developing osteosarcoma. In contrast to the use of PTH 1-34 for osteoporosis, in which therapy is recommended to be stopped after 24 months, a maximum duration of therapy is not defined for rhPTH 1-84 in patients with hypoparathyroidism (1).

#### 4. Summary

Post-surgical hypoparathyroidism and its complication can lead to a desolating quality of life. Thus, clear medical indications of anterior neck surgery and information of complications are mandatory. Close monitoring of calcium and PTH level is also indicated in order to identify hypoparathyroidism before the development of severe and symptomatic hypocalcemia. Although the risk of fracture in hypoparathyroidism is indefinite, this case has spotted the light in its essential as a debilitating complication of chronic hypoparathyroidism. The goal of treatment in hypoparathyroidism is to maintain blood calcium level while preventing symptoms of hypocalcemia. Teriparatide in this case has shown its potential as a parathyroid hormone therapy overcoming refractory hypocalcemia.

#### Acknowledgements

The authors would like to thank Faculty of Medicine, Universitas Airlangga, Surabaya.

#### References

- Gafni RI, Collins MT. Hypoparathyroidism. *New England Journal of Medicine*. 2019;380(18):1738–47.
- Bilezikian JP, Khan A, Potts JT, Brandi ML, Clarke BL, Shoback D, et al. Hypoparathyroidism in the adult: Epidemiology, diagnosis, pathophysiology, target-organ involvement, treatment and challenges for future research. *Journal of Bone and Mineral Research*. 2011;26(10):2317–37.
- Orloff LA, Wiseman SM, Bernet VJ, Fahey TJ, Shaha AR, Shindo ML, et al. American Thyroid Association statement on postoperative hypoparathyroidism: Diagnosis, prevention and management in adults. Vol. 28, *Thyroid*. 2018. 830–841 p.
- Khan AA, Koch CA, van Uum S, Baillargeon JP, Bollerslev J, Brandi ML, et al. Standards of care for hypoparathyroidism in adults: A Canadian and International Consensus. *European Journal of Endocrinology*. 2019;180(3):1–22.
- Shoback DM, Bilezikian JP, Costa AG, Dempster D, Dralle H, Khan AA, et al. Presentation of hypoparathyroidism: Etiologies and clinical features. *Journal of Clinical Endocrinology and Metabolism*. 2016;101(6):2300–12.

- Stack BC, Bimston DN, Bodenner DL, Brett EM, Dralle H, Orloff LA, et al. American Association of Clinical Endocrinologists and American College of Endocrinology Disease State Clinical Review: Postoperative hypoparathyroidism - Definitions and management. *Endocrine Practice*. 2015;21(6):674–85.
- Bilezikian JP, Brandi ML, Cusano NE, Mannstadt M, Rejnmark L, Rizzoli R, et al. Management of hypoparathyroidism: present and future. *The Journal of Clinical Endocrinology and Metabolism*. 2016;101(6):2313–24.
- Clarke BL. Bone disease in hypoparathyroidism. *Arquivos Brasileiros de Endocrinologia e Metabologia*. 2014;58(5):545–52.
- Mannstadt M, Bilezikian JP, Thakker R v, Hanna FM, Clarke BL, Reijnmark L, et al. Hypoparathyroidism. *Nature Reviews Disease Primers*. 2017;3(17055):1–20.
- Mendonça ML, Pereira FA, Nogueira-Barbosa MH, Monsignore LM, Teixeira SR, Watanabe PCA, et al. Increased vertebral morphometric fracture in patients with postsurgical hypoparathyroidism despite normal bone mineral density. *BMC Endocrine Disorders*. 2013;13(May 2014):1–18.
- Gafni RI, Brahim JS, Andreopoulou P, Zhou H, Dempster DW, Collins MT. Daily Parathyroid Hormone 1-34 Replacement therapy for hypoparathyroidism induces marked changes in bone turnover and structure. *Journal of Bone and Mineral Research*. 2012;27(8):1811–20.
- Bollerslev J, Rejnmark L, Marcocci C, Shoback DM, Sitges-serra A, Biesen W van, et al. European Society of Endocrinology Clinical Guideline: Treatment of chronic hypoparathyroidism in adults. *European Journal of Endocrinology*. 2015;173(2):1–20.
- Sinnott BP. Hypoparathyroidism – Review of the literature. *Journal of Rare Disorders: Diagnosis and Therapy*. 2018;4(3):1–7.
- Rubin MR. Recent advances in understanding and managing hypoparathyroidism. *F1000 Research*. 2020;9(766):1–8.
- Starr JR, Tabacco G, Majeed R, Omeragic B, Bandeira L, Rubin MR. PTH and bone material strength in hypoparathyroidism as measured by impact microindentation. *Osteoporosis International*. 2019;1–7.
- Mitchell DM, Regan S, Cooley MR, Lauter KB, Vrla MC, Becker CB, et al. Long-term follow-up of patients with hypoparathyroidism. *The Journal of Clinical Endocrinology and Metabolism*. 2012;97(12):4507–14.
- Upreti V, Somani S, Kotwal N. Efficacy of Teriparatide in patients with hypoparathyroidism: A prospective, open - label study. *Indian Journal of Endocrinology and Metabolism*. 2017;21(11):415–8.